

PHILIPS

Ultrasound

Clinical case study

The eL18-4 Pure Wave linear array with MicroFlow Imaging (MFI) in diagnosis of thyroid cancer, lymph node metastasis, and salivary gland abnormalities

eL18-4 PureWave linear array transducer

Category

Thyroid, Head and Neck, and Lymph Node Assessment

Authors

Lynwood W. Hammers, DO
Consultant Radiologist

Hammers Healthcare Imaging, LLC
New Haven, CT

Overview

Diagnostic ultrasound is the standard for the evaluation and biopsy of thyroid cancer and metastatic lymph nodes. The diagnosis of salivary gland disease has been enhanced by the utilization of diagnostic ultrasound. Ultrasound is the most definitive modality when frequent follow-up exams are required.¹

Patient history

The patient was a 58-year-old female with biopsy-proven thyroid papillary cancer one year prior, with metastatic lymph nodes diagnosed at that time. The patient refused surgery and had returned for reassessment of the thyroid cancer and metastatic lymph nodes. The repeat exam was to assess interval changes as to possible increased aggressiveness and the presence or absence of additional lymph nodes. Increased aggressiveness and metastasis to the lymph nodes would validate the need for surgery.

Protocol

The thyroid and lateral neck lymph nodes were evaluated with the eL18-4 transducer and utilization of MFI vascular assessment.

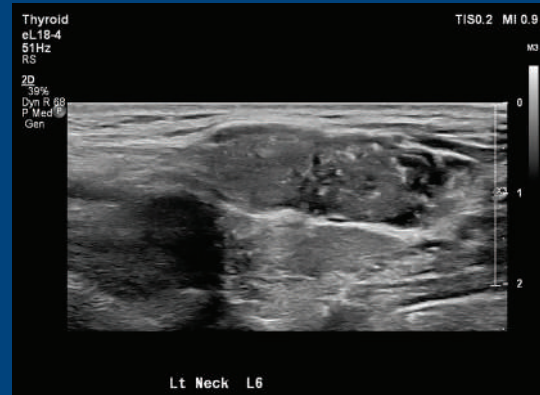
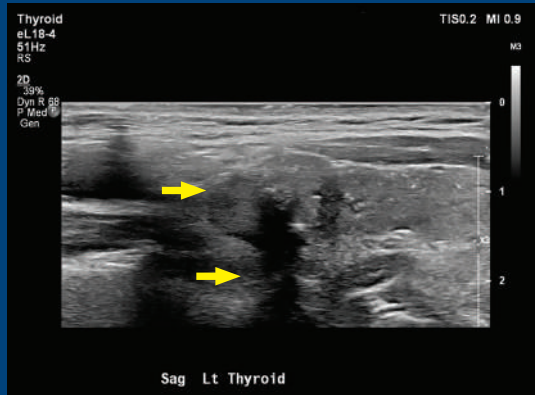
Findings

Imaging with eL18-4 transducer revealed indistinct border at the superior aspect of the mass and posteriorly, raising concern for penetration into soft tissues.

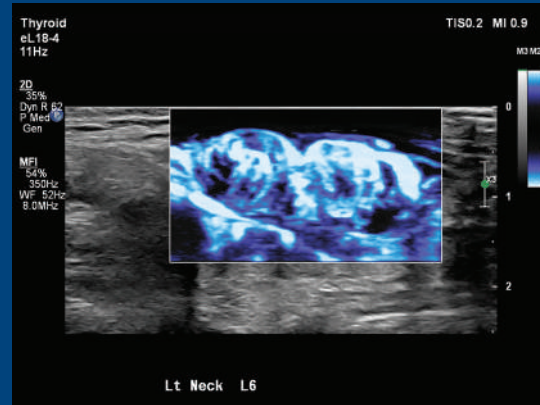
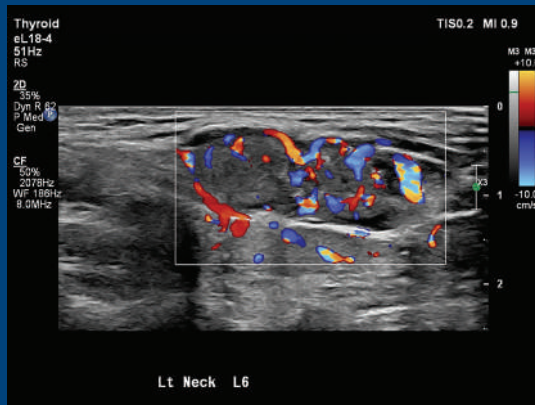
Note the punctate calcification in the lymph nodes shown in the top two images on the next page. MFI of the metastatic lymph nodes as visualized on the bottom right image reveals enhanced draping vascular flow pattern when compared to the right inferior color flow imaging on the bottom left. The internal vasculature is much better delineated with MFI.



The Philips eL18-4 PureWave linear array transducer is our first high-performance transducer featuring ultra-broadband PureWave crystal technology with multi-row array configuration, allowing for fine-elevation focusing capability.



Metastatic lymph node using eL18-4 transducer. Note the punctate calcification in the lymph node.



Same metastatic lymph node using eL18-4 transducer. MFI (right) of the metastatic lymph nodes reveals enhanced draping vascular flow pattern when compared to the Color Doppler imaging (left). The internal vasculature is much better delineated with MFI.

Conclusion

At surgery, there was invasion of adjacent soft issue from the primary thyroid cancer, both anterior and posterior, which was strongly suggested on the eL18-4. This finding convinced the patient to have a definite surgery for staging, with partial removal of the invaded musculature before eventual more aggressive invasion.

MFI revealed lymph node small vessel vascularity to a greater degree. In this case, it did not change the diagnosis. However, future research evaluating the pattern of flow (draping), number of vessels, and possibly other criteria may prove significant in evaluation of normal versus abnormal lymph nodes.

This case clearly demonstrates the increased sensitivity and therefore value of the eL18-4 in staging thyroid cancer. The superb imaging capability of the eL18-4 makes it a superlative transducer for thyroid and head and neck imaging. Thus far, vascular of the thyroid nodules and lymph nodes has not proven to be of great value in evaluation, but this transducer may well change that.

Reference

1 Tessler FN, MD, CM; Hammers LW, DO; et al. ACR Thyroid Imaging, Reporting and Data System (TI-RADS): White Paper of the ACR TI-RADS Committee. JACR 2017.

Results from case studies are not predictive of results in other cases. Results in other cases may vary.